


# Ventral-Onlay Buccal Mucosal Graft Urethroplasty of a Perineal Fistula in a 26-Year-Old Patient With 46 XX Male Syndrome: A Case Report

American Journal of Men's Health  
March-April 1–4  
© The Author(s) 2023  
Article reuse guidelines:  
sagepub.com/journals-permissions  
DOI: 10.1177/15579883231156663  
journals.sagepub.com/home/jmh  


Jalil Hosseini<sup>1</sup>, Arshia Zamani Hajiabadi<sup>2</sup> , and Ali Mohammad Mirjalili<sup>1,3</sup>

## Abstract

Substitution urethroplasty with either a flap or graft is the gold standard for treating long segment urethral strictures. In 1992, Burger and colleagues rediscovered and popularized buccal mucosal graft (BMG). After that El-Kassaby and colleagues, in 1993, used BMG to repair anterior urethral stricture. De la Chapelle syndrome or 46 XX male syndrome is a rare genetic disorder found in 1 in 20,000–25,000 men. This condition described as a presentation of male phenotype along a 46 xx karyotype. In this case report, we report a reconstructive surgery of a 46 XX male syndrome with ambiguous genitalia who presented with the chief complaint of bulbar urethral fistula opened in the perineal space. In this case, we used a buccal mucous graft with the ventral-onlay urethroplasty technique for reconstructing the failed bulbar urethra and closure of the fistula.

## Keywords

buccal mucosal graft, 46 XX male syndrome, reconstructive surgery

Received September 18, 2022; revised January 20, 2023; accepted January 26, 2023

## Introduction

Penile urethral reconstruction is still a noticeable challenge for urologists because even in this era there is no perfect technique to be fully affective for all patients with urethral strictures. Substitution urethroplasty with either a flap or graft is the gold standard for treating long segment urethral strictures (Gonzalez, 2011). In 1992, Burger and co-workers rediscovered and popularized buccal mucosal graft (BMG). After that El-Kassaby and colleagues, in 1993, used BMG to repair anterior urethral strictures. Because of easy harvesting, hairlessness, and compatibility in a wet environment, BMG became an ideal urethral substitute (El-Kasaby et al., 1993; Humby & Higgins, 1941).

De la Chapelle syndrome or 46 XX male syndrome is a rare genetic disorder found in 1 out of 20000–25000 men. This condition is described as a presentation of male phenotype along a 46 xx karyotype. These men mainly show one of these manifestations: (1) normal internal and external genitalia of a 46 XY male,

(2) external genitalia ambiguities, and (3) true hermaphrodites (internal or external genitalia ambiguities) (Yue et al., 2019).

## Case Presentation

A 26-year-old married infertile man presented with the chief complaint of perineal fistula. The patient was born in 1994 with ambiguous genitalia. At birth, he had no

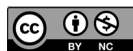<sup>1</sup>Men's Health and Reproductive Health Research Center, Shahid Beheshti University of Medical Sciences and Shahid Beheshti University, Tehran, Iran

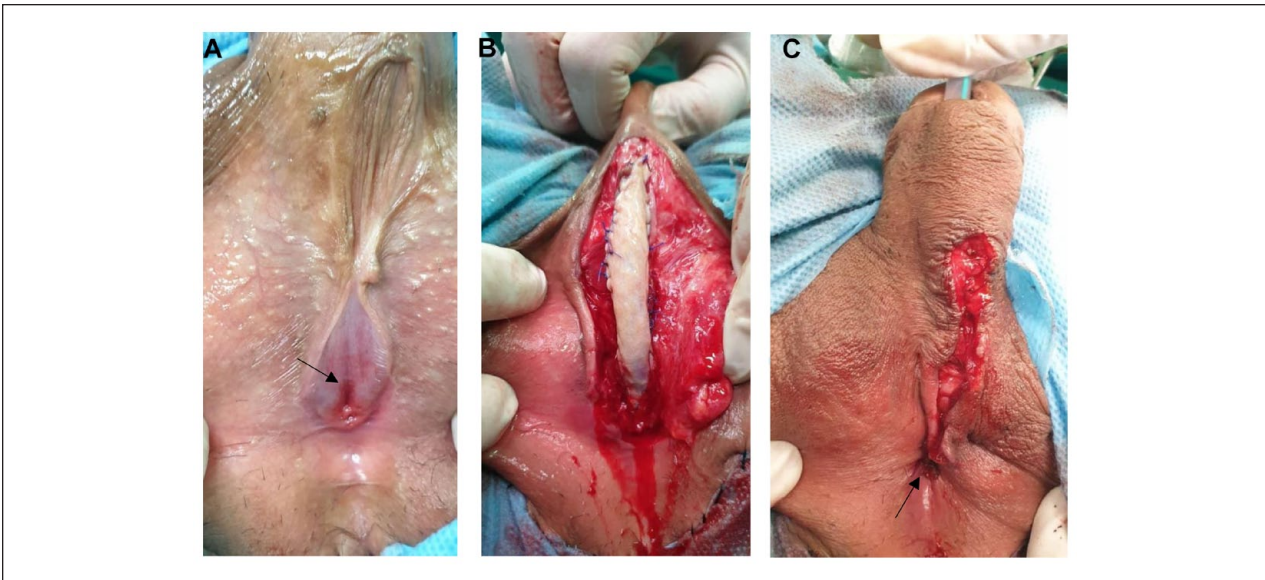
<sup>2</sup>Student Research Committee, School of Medicine, Mazandaran University of Medical Sciences, Sari, Iran

<sup>3</sup>Reconstructive Urologist, Yazd Urology Department, Men's Health, and Reproductive Health Research Center, Yazd, Iran

## Corresponding Author:

Ali Mohammad Mirjalili, Men's Health and Reproductive Health Research Center, Shahid Beheshti University of Medical Sciences and Shahid Beheshti University, Tehran 19839-63113, Iran.  
Email: aliaskari56@yahoo.com



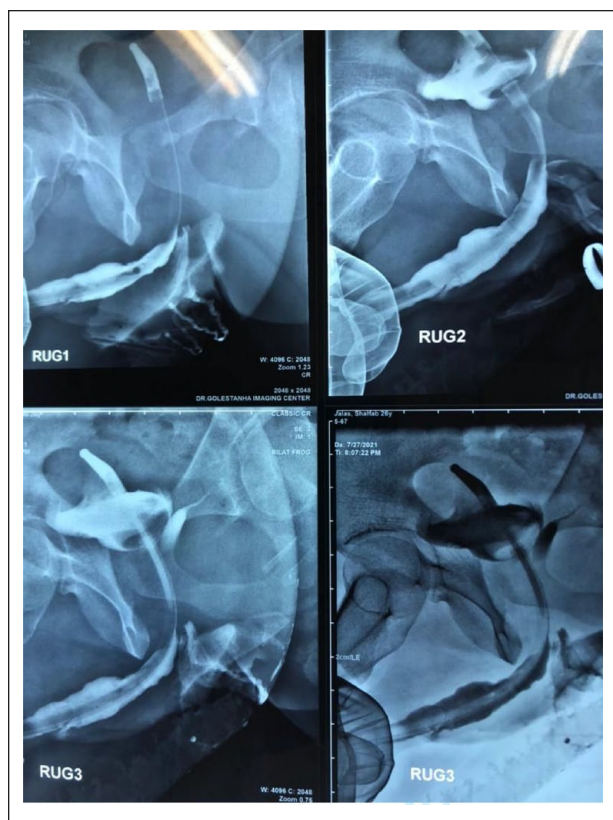


**Figure 1.** (A) Pre-Operation/The Meatus of Fistula Shown by the Black Arrow Just Superior to the Vaginal Orifice; (B) Buccal Mucosal Graft Fixed on the Plate and Reconstructed Failed Bulbar Urethra; (C) Post-Operation/The Pit of the Undeveloped Vaginal Canal Which Was Left Open Due to Lack of Enough Supporting Tissue Around the Plate Shown by the Black Arrow

noticeable scrotal sac containing no testes to palpate and had micro-penis with hypospadias in examination, and there was a fossa inferior to the penis indicating a non-developed vaginal canal. Abdominopelvic sonography of the newborn baby showed no sign of uterus and ovaries in pelvic space and revealed a 15 mm mass in the right inguinal canal strongly indicating an undescended testis. Ultimately, genome karyotyping and physical examination and laboratory findings lead to the diagnosis of 46 XX male syndrome. With the opinion of the physician based on findings of karyotyping and physical examination, hormone therapy with testosterone injection was started for him. The recent abdominopelvic sonography also showed the undescended right testis with diameter of 16 × 10 mm with normal epididymis head echo pattern in inguinal canal, and there was no evidence of the left testis in scrotal sac or left inguinal canal. The other genitourinary system organs including kidneys, bladder, and prostate seemed to be normal. All laboratory findings were within normal limits, and there were no noticeable findings except high levels of follicular stimulating hormone (34.94 mIU/ml) and luteinizing hormone (16.6 mIU/ml) hormones. The patient seemed to be satisfied with his sexual function, and as he declared, he had normal erection and ejaculation, but in further investigation, non-obstructive azoospermia was diagnosed with semen analysis test. In physical examination, the scar of his previous Orchidopexy and hypospadias repair surgery at the age of 8 was evident. The fistula was reconstructed with two plates (proximal and distal) using the repaired site skin that resulted to a complete failure, and there was an

8–9 cm recurrent fistula developed from the inlet of the undeveloped vaginal canal (Figure 1A).

In this case, we used ventral-onlay BMG urethroplasty to reconstruct the bulbar urethral urethra. Before starting the reconstruction surgery, cystoscopy was done, and patency of the urethra was evaluated. After general anesthesia, an 8-cm buccal mucous graft of the inner layer of the patient's cheek was taken and the patient prepared for oral mucosal graft Urethroplasty with the rigid 17F cystoscope. For this case, a vaginectomy was done, and the vaginal canal and the meatus were separated with a plate. After revealing urethra with incision of perineum and bulbospongiosum muscle from the site of the meatus and harvesting and trimming the buccal graft, it was used as ventral onlay and sutured with multi 4-0 vicryl on Silastic catheter 18F (Figure 1B). After grafting the buccal mucosa, we used the surrounding plate's tissue to support the graft and sutured the layers on the graft. We achieved nearly complete closure of the fistula with good supportive tissue but, as supporting tissues were not adequate for total closure of the undeveloped vaginal canal, a little pit on the inferior part of the plate at the site of the vaginal canal was left open after surgery as shown in Figure 1C. In this case, the undescended right testis was also fixed in the scrotal sac. After 3 weeks, a Retrograde Urethrography (RUG) showed contrast extravasation in the proximal part of the fistula (Figure 2), so we kept the catheter fixed for another week. Another RUG was done after a week prior to catheter removal confirmed absence of extravasation so we removed the catheter. In 1-year follow-up, results were satisfying, and there was no evidence of graft



**Figure 2.** Retrograde Urethrography 3 Weeks After the Operation Showing Contrast Extravasation in Proximal Part of the Fistula

failure or a probable fistula development in physical exam and control RUG done 6 months later.

## Discussion

Several kinds of grafts are used in urethroplasty, the most common technique in reconstructive surgery for penile strictures and injuries. Each one of them has its own advantages and disadvantages. Two of these grafts are BMG and local penile graft (LPG). A 92.9% success rate has been reported for BMG versus an 85.7% success rate for LPF confirming our graft choice (Ali et al., 2019). We used BMG as the graft of choice for our patient because of its effectiveness and our evaluation of the patient's condition.

There are multiple techniques in such surgeries such as ventral-onlay, dorsal-onlay, dorsal-inlay, lateral-onlay, and dorsolateral-onlay. Ventral-onlay would not assure sufficient nutritional and mechanical support because of lack of proper graft's vascular supply but an 88.9% success rate of ventral-onlay has been reported in one study (Jinga et al., 2013). Other techniques seem to show good overall results. Success rates of 83%, 86.7%, 90.1%, 79%, and 70% have been reported for lateral-onlay,

Asopa (dorsal-inlay), Palminteri (combined ventral and dorsal onlay), dorsolateral-onlay and dorsal-onlay, respectively (Mangera et al., 2011; Pathak et al., 2017). Jiang and colleagues reported a success rate of 88.5% in the combined technique group against the success rate of 72.5% in the single technique group (Jiang et al., 2015).

Using a specific technique and graft tissue for the surgery depends on the patient's situation and the surgeon's evaluation of probable outcome, but according to the literature, it seems that the combined technique appears to be more effective with better outcome in follow-ups. We used the ventral-onlay technique and BMG; the outcome was satisfying, and there was no evidence of any complication or graft failure signs or recurrent fistula and urethral strictures in 1-year follow-up. First evidence of postoperation extravasation that was evident in postoperation RUG was absent in pre-catheter removal and follow-up RUG. The little pit that left open was due to lack of enough supporting tissues. In our postoperation evolutions, this pit seemed to be superficial and without any communication with deeper layers so it was less likely to be the source of extravasation.

## Conclusion

We reported a reconstructive surgery of a 46 XX male syndrome with ambiguous genitalia who presented with chief complaint of bulbar urethral fistula opened in the perineal space. In this case, we used ventral-onlay technique and BMG to recreate the failed urethra, and the results were satisfying.

## Acknowledgments

This article is taken from disease registry, titled "Establishment of a national registry system for patients undergone reconstructive urology procedures" and code number IR.SBMU.RETECH.REC.1399.688 from ethic committee, that was supported by deputy of research and technology in Shahid Beheshti University of medical science (<http://dregistry.sbm.ac.ir>). The authors thank the patient for their sincere collaboration.

## Declaration of Conflicting Interests

The author(s) declared no potential conflicts of interest with respect to the research, authorship, and/or publication of this article.

## Funding

The author(s) received no financial support for the research, authorship, and/or publication of this article.

## Consent for Publication

Written informed consent was obtained from the patient for publication of this case report and any accompanying images. A copy of this written consent is available for review by the editor of the journal.

**ORCID iD**

Arshia Zamani Hajiabadi  <https://orcid.org/0000-0001-7422-5892>

**References**

- Ali, A. I., Hamid, A. A., Abdel-Rassoul, M. A., Galal, E. M., Hasanein, M. G., Hassan, M. A. E., & El-Hawy, M. M. (2019). Buccal mucosal graft versus penile skin flap urethroplasty for long segment penile urethral stricture: A prospective randomized study. *Central European Journal of Urology*, *72*(2), 191–197.
- El-Kasaby, A., Fath-Alla, M., Noweir, A., El-Halaby, M., Zakaria, W., & El-Beialy, M. (1993). The use of buccal mucosa patch graft in the management of anterior urethral strictures. *The Journal of Urology*, *149*(2), 276–278.
- Gonzalez, C. (2011). Flap. *The Journal of Urology*, *186*(2), 376–377.
- Humby, G., & Higgins, T. T. (1941). A one-stage operation for hypospadias. *British Journal of Surgery*, *29*(113), 84–92.
- Jiang, J., Zhu, Y., Jiang, L., Luo, D., Wei, X., Wazir, R., Li, H., & Wang, K. (2015). Combined dorsal plus ventral double-graft urethroplasty in anterior urethral reconstruction. *Indian Journal of Surgery*, *77*(3), 996–1000.
- Jinga, V., Hurduc, M., Voinescu, V., Filipoiu, F., & Balgradeanu, M. (2013). Ventral buccal mucosa graft urethroplasty for penile urethral strictures: A predictable failure. *Chirurgia*, *108*(2), 245–249.
- Mangera, A., Patterson, J. M., & Chapple, C. R. (2011). A systematic review of graft augmentation urethroplasty techniques for the treatment of anterior urethral strictures. *European Urology*, *59*(5), 797–814.
- Pathak, H. R., Jain, T. P., Bhujbal, S. A., Meshram, K. R., Gadekar, C., & Parab, S. (2017). Does site of buccal mucosa graft for bulbar urethra stricture affect outcome? A comparative analysis of ventral, dorso-lateral and dorsal buccal mucosa graft augmentation urethroplasty. *Turkish Journal of Urology*, *43*(3), 350–354.
- Yue, F., Zhang, H., Xi, Q., Jiang, Y., Li, L., Liu, R., & Wang, R. (2019). Molecular cytogenetic analysis and genetic counseling: A case report of eight 46, XX males and a literature review. *Molecular Cytogenetics*, *12*(1), 1–6.